

Clinical Research

Neurological outcomes after corpectomy with autologous grafts versus expandable titanium cages: A pilot study



Resultados neurológicos después de corpectomía con injertos autólogos versus cajas de titanio expandibles: un estudio piloto

Alexis Manuel Portillo-González^{a,b}, Julio César López-Valdés^{a,b,c,*}, Daniel Alejandro Vega-Moreno^{b,d}, Óscar Medina-Carrillo^a, Abraham Ibarra-De la Torre^a, Ulises García-González^a

^a Department of Neurosurgery, South Central High Specialty Hospital (PEMEX), Tlalpan, Mexico City, Mexico

^b Postgraduate Department, National Autonomous University of Mexico, Ciudad Universitaria, Mexico City, Mexico

^c Research Department, Autonomous Tamaulipas University, Medicine Faculty of Tampico "Dr. Alberto Romo Caballero", Tampico, Tamaulipas, Mexico

^d Department of Oncological Neurosurgery, Regional Hospital of Toluca, ISSEMYM, Toluca de Lerdo, Mexico State, Mexico

ARTICLE INFO

Keywords:

Corpectomy
Expandable cages
Autograft
Neurological outcome
Spinal fusion

ABSTRACT

Background: Vertebral corpectomy is a common surgical technique for spinal decompression and fusion. This retrospective pilot study compares the neurological outcomes of corpectomy using autologous bone grafts versus expandable titanium cages.

Methods: In this retrospective pilot study of 40 patients, we compared autologous bone grafts versus expandable cages for single- or multi-level corpectomy. We assessed pre- and postoperative mJOA (Modified Japanese Orthopedic Association) scores. To account for baseline imbalances, we performed analysis of covariance (ANCOVA) adjusting for age and preoperative mJOA, and inverse probability of treatment weighting (IPTW) based on propensity scores. Outcomes included postoperative mJOA, Δ mJOA, responder rate (≥ 2 -point improvement), and Hirabayashi recovery rate.

Results: Both groups showed significant neurological improvement. Adjusted for preoperative mJOA, the ANCOVA model found that the titanium group presented significantly higher postoperative mJOA scores after adjustment (ANCOVA coefficient = +2.50, $p = 0.0007$). IPTW-weighted regression showed a trend toward greater neurological improvement with titanium (coefficient = +1.75, $p = 0.092$), with satisfactory covariate balance. Clinically meaningful recovery was observed in 100% of titanium cases versus 75% of autologous cases ($p = 0.064$). The Hirabayashi recovery rate was also superior with titanium (mean 65.0%) compared to autologous grafts (mean 45.1%).

Conclusion: Both techniques provided similar and effective neurological outcomes after corpectomy. Our findings suggest that neurological recovery is more strongly influenced by the preoperative severity of the myelopathy than by the surgical system used. Both are viable options for corpectomy and warrant larger-scale studies.

RESUMEN

Antecedentes: La corpectomía vertebral es una técnica quirúrgica común para la descompresión y fusión espinal. Este estudio piloto retrospectivo comparó los resultados neurológicos de la corpectomía utilizando injertos óseos autólogos versus jaulas de titanio expandibles.

Métodos: En este estudio de 40 pacientes, se evaluaron las puntuaciones pre y postoperatorias del Modified Japanese Orthopedic Association (mJOA). Se utilizó un análisis de covarianza (ANCOVA) y una ponderación por probabilidad inversa de tratamiento (IPTW) para ajustar por variables como la edad y la puntuación de mJOA inicial. Los resultados medidos incluyeron la tasa de respuesta (≥ 2 puntos de mejora) y la tasa de recuperación de Hirabayashi.

Palabras clave:

Corpectomía
Cajas expandibles
Autoinjerto
Resultado neurológico
Fusión espinal

* Corresponding author.

E-mail addresses: jc.lopez@live.com, jc.lopez@comunidad.unam.mx (J.C. López-Valdés).

<https://doi.org/10.1016/j.neucie.2025.500732>

Received 15 July 2025; Accepted 3 September 2025

Available online 25 November 2025

2529-8496/© 2025 The Author(s). Published by Elsevier España, S.L.U. on behalf of Sociedad Española de Neurocirugía. This is an open access article under the CC BY-NC-ND license (<http://creativecommons.org/licenses/by-nc-nd/4.0/>).

Resultados: Ambos grupos mostraron una mejora neurológica significativa. El grupo de titanio presentó puntuaciones de mJOA significativamente más altas después de los ajustes por ANCOVA ($p = 0,0007$). La regresión ponderada por IPTW mostró una tendencia hacia una mayor mejora neurológica con titanio ($p = 0,092$). Se observó una recuperación clínicamente significativa en el 100% de los casos con titanio versus 75% con injertos autólogos ($p = 0,064$). La tasa de recuperación de Hirabayashi también fue superior en el grupo de titanio (media: 65,0%) en comparación con el de injertos autólogos (media: 45,1%).

Conclusión: Ambas técnicas proporcionaron resultados neurológicos similares y efectivos. Los hallazgos sugieren que la recuperación neurológica está más influenciada por la gravedad preoperatoria de la mielopatía que por el sistema quirúrgico utilizado. Ambas opciones son viables y justifican la realización de estudios a mayor escala.

Introduction

Cervical spinal pathologies, encompassing degenerative conditions, trauma, infections, and tumors, are significant causes of myelopathy and radiculopathy, often necessitating surgical intervention to alleviate neural compression and stabilize the spinal column.^{1–3} Among the various surgical techniques, anterior cervical corpectomy has become a widely utilized and effective approach, particularly when the pathology involves the vertebral body, allowing for extensive decompression of the spinal cord and nerve roots.

Corpectomy is a surgical technique that provides extensive decompression and fusion at the cervical level and is also used for certain thoracic pathologies. It is considered more complex compared to traditional anterior cervical discectomy and fusion,¹ as is thoracic corpectomy, which can be performed through various approaches such as anterior (supra-sternal or trans-sternal), dorsolateral, or costotransverse.² The surgeon's experience plays a crucial role in each case. Thoracic pathologies are often traumatic or neoplastic, whereas cervical pathologies are primarily degenerative.³ Corpectomy is indicated for a wide range of conditions including degenerative disc disease, traumatic injuries, tumors,⁴ infectious lesions, and posterior longitudinal ligament calcification.^{5,6} It offers diverse radiological and clinical outcomes,^{7,8} and in some series, is comparable to anterior cervical discectomy and fusion in terms of effectiveness.^{9,10}

The procedure is associated with complications such as dysphagia (5.3%), esophageal perforation (0.2%), recurrent laryngeal nerve paralysis (1.3%), infection (1.2%), adjacent segment disease (8.1%), pseudoarthrosis (2.0%), graft or hardware failure (2.1%), cerebrospinal fluid leakage (0.5%), hematoma (1.0%), and Horner's syndrome (0.4%).^{11,12} The global hospital mortality rate is 1.6%, with a complication rate of 18.4% and a median hospital stay of 6 days. Having three or more spinal levels treated and a surgery duration exceeding 6 h are significant predictors of postoperative complications.¹³ Controversies exist regarding surgical techniques due to these complications, though some series suggest that the complications are similar to other anterior approaches.¹⁴ Advantages of corpectomy in multi-level disease, particularly cervical, include shorter surgical times but increased intraoperative blood loss, which is proportional to the number of levels treated. Comparing corpectomy to anterior cervical discectomy and fusion, there are almost no differences in multi-level disease, making it a safe procedure.¹⁵

This procedure advantages include direct access to the pathology and the ability to achieve broad decompression and subsequent spinal fusion, leading to improved neurological outcomes. Corpectomy is the treatment of choice for certain cervical and thoracic conditions, offering excellent decompression, though its stability for multi-level disease still warrants debate. Each case should be individually assessed to determine the best surgical approach and material.¹⁶

Historically, autologous bone grafts, typically harvested from the iliac crest or fibula, were the gold standard for reconstructing the spinal column after corpectomy due to their osteoconductive, osteoinductive, and osteogenic properties.¹⁶ However, their use is associated with considerable drawbacks, including donor site morbidity (e.g., pain, hematoma, infection, fracture), limited graft availability, and potential for graft collapse or resorption. These limitations have driven the development and adoption of alternative reconstructive materials, such as allografts and, more recently, various types of metallic cages.^{16–18}

Over the years, new prosthetic materials such as titanium cages have been implemented, showing safety and good results in various studies.^{17–20} While bone grafts are still used, innovative techniques are being explored.²¹ Expandable titanium cages have emerged as a promising alternative, offering several theoretical advantages. They can be precisely expanded in situ to achieve optimal distraction and restoration of spinal alignment, potentially reducing the risk of subsidence and providing immediate biomechanical stability. Moreover, their use eliminates the need for a second surgical site, thereby mitigating donor-site complications. While studies have demonstrated the safety and efficacy of these prosthetic implants, and their non-inferiority to traditional methods in many aspects, a comprehensive understanding of their comparative neurological outcomes against autologous bone grafts remains an area of ongoing investigation.

The aim of this study was to retrospectively compare the neurological outcomes, clinical improvement, complications, and technical parameters between autologous bone grafts and an advanced expandable titanium cage system for vertebral body reconstruction following cervical corpectomy.

Materials and methods

Study design and patient selection

This was a retrospective, observational, comparative pilot study conducted at a tertiary care center. The study included adult patients who underwent anterior cervical or thoracic corpectomy between January 2013 and December 2023. Patients were selected using a convenience sampling method, based on the International Classification of Diseases, 10th Revision (ICD-10). A primary investigator (A.M.P.G.) manually collected data on a daily basis from the electronic clinical file. Participants of this study were recruited from a tertiary care center in Mexico City, the capital and largest city of Mexico.

All patients had a diagnosis of cervical disc disorder with myelopathy (ICD-10: M50.0) or related spinal cord compression syndromes, including trauma, degenerative disease, and tumors requiring anterior vertebral body reconstruction.

Patients were divided into two groups based on the type of reconstructive material used:

Group A: Patients who received artificial implants: expandible titanium cages (ADD plus™ <Ulrich medical> or Te-Corp™ <SMG>).

Group B: Patients reconstructed with autologous bone grafts (vascularized or non-vascularized fibula or iliac crest).

Inclusion criteria were: age > 18 years, complete pre- and postoperative clinical records, and follow-up of at least three months. Patients with active infection, systemic bone disease, or revision surgery within the first three months were excluded. Exclusion criteria were patients who had incomplete clinical records, treatment, or follow-up notes. Patients with confirmation of an alternative diagnosis such as plasma cell cancer (e.g., myeloma) were also excluded.

This research adhered to the principles outlined in the Declaration of Helsinki. The institutional review board approved this study (register number 85-23), granting a waiver for informed consent.

Surgical technique

All surgeries were performed using a standard anterior cervical or thoracic approach. After corpectomy and decompression, either an expandible titanium cages (ETC) or an autologous bone graft (fibula or iliac crest) was placed, followed by anterior plate fixation when required.

Clinical and surgical variables

The following data were collected: Age, sex, pre- and postoperative modified Japanese Orthopaedic Association (mJOA) score,²² length of hospital stay, number of vertebral levels treated, operative time (min), intraoperative blood loss (mL), and complications (e.g., infection, hardware failure).

Electronic data from the clinical records of diagnosed patients was collected, following the STROBE²³ recommendations.

The Δ mJOA score was calculated as the difference between postoperative and preoperative mJOA.

Also, the neurological recovery was further quantified using the Hirabayashi recovery rate,^{24–26} which accounts for baseline neurological status. The recovery rate was calculated for each patient using the following formula:

$$\text{Recovery rate (\%)} = \frac{\text{PostoperativemJOA} - \text{Preoperative mJOA}}{17 - \text{PreoperativemJOA}} \times 100$$

where 17 represents the maximum possible mJOA score. This measure provides a standardized estimate of neurological improvement, minimizing the influence of preoperative status on postoperative outcomes. Group comparisons were performed using descriptive statistics and graphical analysis.

Statistical analysis

Continuous variables were expressed as the mean \pm standard deviation ($\mu \pm$ SD) and were compared using Student's *t*-test or the Mann–Whitney *U* test, based on normality assessed with the Shapiro–Wilk test. Categorical variables were analyzed with the Chi-squared or Fisher's exact test, and odds ratios (OR) were calculated for complications.

Given that preoperative mJOA scores were significantly different between the groups (Δ mJOA), adjusted analyses were performed to mitigate this baseline imbalance. An ANCOVA model was used, controlling for preoperative mJOA score and age, to compare postoperative scores. Furthermore, to strengthen the validity of our findings, we applied an inverse probability of treatment weighting (IPTW) analysis using pro-

pensity scores based on age and preoperative mJOA. For all analyses, a *p*-value < 0.05 was considered statistically significant.

Statistical analysis was performed using Excel™ for the initial findings, and SPSS™ version 20 for adjusted analyses.

Results

A total of 48 patients were obtained. Following a thorough screening process, 40 patients were enrolled in the study, with 20 undergoing corpectomy with artificial implants (ADD plus™/Te-Corp™) and 20 receiving reconstructions with autologous bone grafts (fibula or iliac crest), Fig. 1. The two groups were compared across multiple demographic and clinical variables (Table 1 and Fig. 2).

The mean age of patients in the ADD plus™/Te-Corp™ group was 58.5 ± 11.3 years, while the autologous graft group had a mean age of 65.1 ± 9.8 years ($p = 0.055$). Although the difference was not statistically significant, a trend toward older age was observed in the autologous graft group. The sex distribution showed a higher male-to-female ratio in the ADD plus™/Te-Corp™ group (2.33:1) compared to the autologous graft group (1.22:1) (Table 2).

Neurological outcomes

Patients treated with expandible titanium cages had significantly lower preoperative mJOA scores (8.95 ± 3.03) compared to those in the autologous graft group (11.25 ± 3.5 ; $p = 0.0323$), suggesting greater initial neurological impairment. However, the postoperative mJOA scores were similar between groups (13.75 ± 2.15 vs. 12.9 ± 3.78 ; $p = 0.3875$). The mean improvement in mJOA was significantly greater in the ADD plus™/Te-Corp™ group (4.8 ± 1.85 vs. 2.2 ± 0.87 ; $p = 0.0001$), indicating superior neurological recovery (Fig. 3).

Baseline neurological function, measured with the mJOA scale, differed significantly between treatment groups, introducing a potential source of bias. To account for this, we performed adjusted analyses.

An ANCOVA model, controlling for preoperative mJOA and age, showed that patients treated with titanium cages had significantly higher postoperative mJOA scores compared to those treated with autologous grafts (adjusted coefficient = +2.50, $p = 0.0007$).

To further reduce baseline imbalances, we applied inverse probability of treatment weighting (IPTW) using propensity scores estimated from age and preoperative mJOA, Fig. 4. After weighting, covariate balance improved substantially, with standardized mean differences falling below conventional thresholds. The IPTW-weighted regression indicated a trend toward better neurological outcomes in the ETC group (coefficient = +1.75, $p = 0.092$), although this result did not reach conventional statistical significance.

Regarding clinically meaningful improvement, the responder rate (≥ 2 -point increase in mJOA) was 100% in the ETC group versus 75% in the autologous group ($p = 0.064$).

Taken together, these results suggest that, after adjustment for baseline neurological status, titanium cages are associated with greater neurological recovery compared to autologous grafts. The IPTW analysis supports the robustness of this association, although weighted models indicate that the effect size may be more modest than suggested by the unadjusted comparison.

Also, the mean Hirabayashi recovery rate was $65.0 \pm 27.9\%$ in the titanium group and $45.1 \pm 65.2\%$ in the autologous graft group. Median recovery rates were 65.2% and 36.4%, respectively. The distribution of recovery rates is illustrated in Fig. 4.

Table 1
Demographic and clinical characteristics of the study population.

No.	Sex	Age(years)	No. of levels	Levels	Im-plant	HIS (days)	Compli-cations	mJOA Pre-Op	mJOA Post-Op	ΔmJOA	Surgical interventions	Evolu-tion (months)	Diagnosis	Blood loss (mL)	Surgi-cal time (min)
1	M	64	3	C4-C5-C6	ADD+	4	N/A	8	12	4	N/A	360	Myelopathy	255	300
2	M	59	3	C5-C6-C7	ADD+	9	N/A	10	15	5	N/A	28	C6 Fracture	240	700
3	F	61	3	C4-C5-C6	ADD+	4	N/A	12	18	6	N/A	720	Radiculopathy	225	200
4	M	41	1	C3	ADD+	5	N/A	5	12	7	Previous cervical decompression	150	Cervical Myelopathy	270	500
5	M	48	1	T2	ADD+	68	N/A	7	12	5	Previous posterior decompression	120	T2 Fracture	244	800
6	M	69	3	C5-C6-C7	ADD+	24	N/A	7	13	6	N/A	45	EDD with Myelopathy	250	450
7	F	28	1	C4	ADD+	16	N/A	15	18	3	N/A	60	C4 Fracture	190	400
8	M	61	1	C4	ADD+	13	N/A	14	16	2	N/A	300	C4 Fracture + Radiculopathy	210	350
9	F	70	2	C5-C6	Te-Corp™	4	N/A	14	16	2	N/A	1440	EDD Radiculopathy	180	250
10	F	50	2	T6-T7	Te-Corp™	53	Pneumonia	8	14	6	N/A	2	T6/T7 Fracture (ASIA A)	280	1300
11	M	64	2	C4-C5	ADD+	4	N/A	8	12	4	N/A	360	EDD Myelopathy	290	800
12	M	71	1	C4	ADD+	5	N/A	11	15	4	N/A	90	EDD Myelopathy	240	100
13	M	51	2	C4-C5	ADD+	4	N/A	8	14	6	Previous ACDF	150	EDD Myelopathy	249	500
14	M	58	2	C5-C6	ADD+	16	N/A	10	15	5	N/A	30	Klippel-Feil Syndrome C5-C6	270	550
15	M	67	4	C4-C5-C6-C7	ADD+	4	N/A	10	12	2	N/A	1080	EDD Myelopathy	300	450
16	M	64	2	C6-C7	ADD+	25	Surgical infection	8	10	2	Subsequent surgical lavage	60	Traumatic spinal cord injury C7	220	600
17	M	75	3	C5-C6-C7	Te-Corp™	5	N/A	8	14	6	N/A	360	EDD Myelopathy	260	450
18	F	50	2	C4-C5	Te-Corp™	4	N/A	6	13	7	N/A	N/A	Myelopathy	220	450
19	F	62	3	C5-C6-C7	ADD+	5	N/A	4	12	8	N/A	N/A	Myelopathy	240	500
20	M	56	3	C4-C5-C6	ADD+	4	N/A	6	12	6	N/A	N/A	Myelopathy	290	750

Table 1 (Continued)

No.	Sex	Age (years)	No. of levels	Levels	Implant	HIS (days)	Complications	mJOA Pre-Op	mJOA Post-Op	ΔmJOA	Surgical interventions	Evolution (months)	Diagnosis	Blood loss (mL)	Surgical time (min)
21	F	66	2	C6-C7	Fibula	25	N/A	9	10	1	Previous ACDF	30	Previous ACDF failure	300	200
22	F	58	2	C3-C4	Fibula	26	N/A	6	7	1	N/A	14	C3 Fracture	29	600
23	M	61	3	C4-C5-C6	Fibula	4	N/A	10	12	2	Previous ACDF	360	EDD Myelopathy	314	500
24	F	52	1	C5	Fibula	5	N/A	15	16	1	N/A	360	EDD Radiculopathy	280	200
25	M	65	2	C5-C6	Fibula	4	N/A	6	10	4	N/A	180	EDD Myelopathy	320	350
26	M	56	2	C6-C7	Fibula	38	N/A	10	12	2	Previous ACDF C5-C6	360	EDD Myelopathy	436	300
27	M	70	2	C5-C6	Fibula	5	N/A	14	16	2	N/A	1440	EDD Radiculopathy	345	500
28	F	72	1	C6	Iliac crest	15	CSF fistula	15	15	1	Previous ACDF C5-C6/C6-C7	720	EDD Radiculopathy	180	400
29	F	38	2	C4-C5	Iliac crest	17	N/A	13	15	2	N/A	720	EDD Myelopathy	130	200
30	F	78	1	C4	Fibula	9	N/A	14	16	2	Previous ACDF C4-C5/C5-C6	180	EDD Myelopathy	300	100
31	F	63	1	C5	Iliac crest	5	N/A	15	18	3	Previous ACDF C4-C5/C5-C6	120	EDD Radiculopathy	225	200
32	M	82	1	C6	Iliac crest	4	N/A	14	16	2	Previous ACDF C5-C6/C6-C7	360	EDD Radiculopathy	210	200
33	M	75	3	C5-C6-C7	Iliac crest	5	N/A	16	18	2	N/A	1800	EDD Myelopathy	225	1000
34	M	70	2	C3-C4	Fibula	14	N/A	14	16	2	N/A	720	EDD Myelopathy	225	150
35	F	69	2	C4-C5	Fibula	5	N/A	12	5	3	N/A	2160	EDD Myelopathy	180	200
36	M	67	2	C4-C5	Fibula	39	Post-op pneumonia	8	11	3	N/A	180	Myelopathy/subligamentary abscess C4-C5	330	150
37	F	72	1	C6	Iliac crest	29	CSF fistula	14	17	3	Previous ACDF C5-C6	720	EDD Radiculopathy	155	400
38	M	65	2	C5-C6	Fibula	10	N/A	6	10	4	N/A	300	EDD Myelopathy	285	750
39	M	58	2	C4-C5	Fibula	21	SSI	6	8	2	N/A	150	EDD Myelopathy	340	600
40	M	65	1	C6	Fibula	7	N/A	8	10	2	N/A	90	EDD Myelopathy	360	450
Total (N = 40)	M 25 vs. F 15	$\mu = 61.78 \pm 1.95$	$\mu = 1.98 \pm 0.81$ levels	Various	20 vs. 20	$\mu = 14.08 \pm 13.91$ days	Various	$\mu = 10.10 \pm 3.53$ points	$\mu = 13.33 \pm 3.23$ points	$\mu = 3.50 \pm 2.05$ points	Yes = 17/no = 23	$\mu = 440.8 \pm 520.2$ months	Various	$\mu = 298.1 \pm 147.2$ mL	$\mu = 388.7 \pm 220.6$ min

ACDF, anterior cervical discectomy and fusion; C, cervical (vertebra); CSF, cerebrospinal fluid; Δ, delta (change); EDD, extradural disease/degenerative disc disease; F, female; IHS, in-hospital stay; M, male; mJOA, Modified Japanese Orthopaedic Association; N/A, not applicable/not available; No., number; Pre-Op, preoperative; Post-Op, postoperative; SSI, surgical site infection; T, thoracic (vertebra).

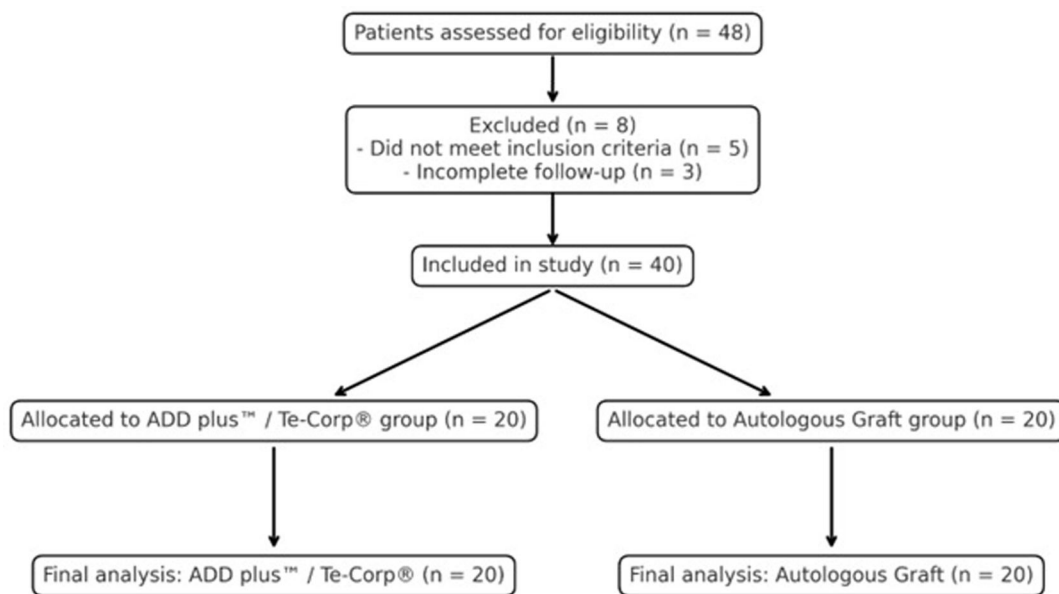


Fig. 1. Patient distribution by surgical technique. Flowchart showing the selection of 48 patients initially considered for inclusion. After applying exclusion criteria, 40 patients were retained for final analysis: 20 underwent reconstruction with autologous bone grafts (fibula or iliac crest) and 20 received expandable titanium cages (ADD plus™/Te-Corp™).

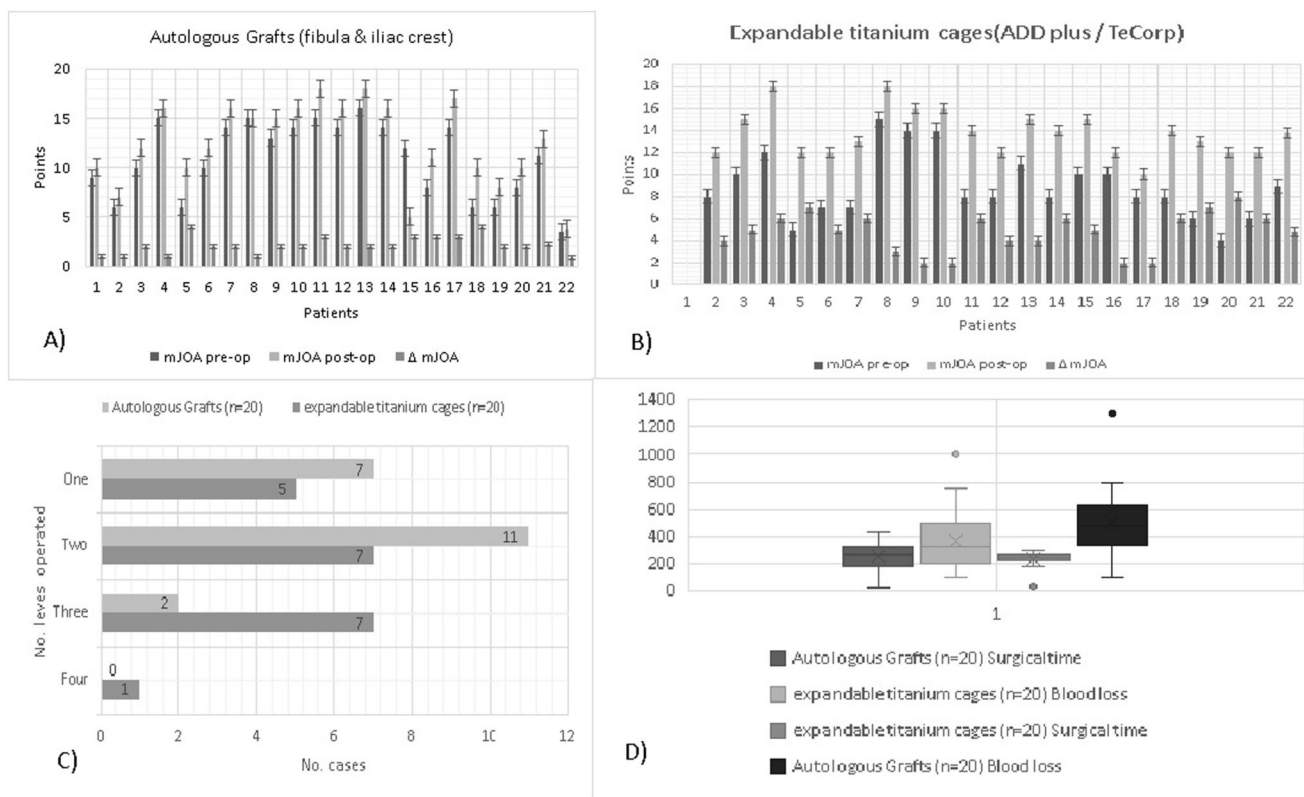


Fig. 2. Comparative summary of surgical and clinical parameters. Bar chart illustrating key variables between the two groups, including Δ mJOA score, surgical time, intraoperative blood loss, hospital stay, and levels treated. Note the significantly greater neurological improvement in the ADD plus™/Te-Corp™ group.

Surgical parameters and complications

No significant differences were found in surgical time (246.15 ± 33.34 vs. 258.45 ± 92.32 min; $p = 0.5604$) or length of hospital stay (13.8 ± 17.5 vs. 14.35 ± 11.27 days; $p = 0.1182$) between

the groups. Blood loss was higher in the ADD plus™/Te-Corp™ group (520 ± 263.78 mL) compared to the autologous graft group (372.5 ± 227.75 mL), though this difference did not reach statistical significance ($p = 0.0660$) (Fig. 1d).

Table 2

Comparative analysis between autologous graft and expandable titanium cage groups. Includes means, standard deviations, and *p*-values for each variable. Statistically significant values are highlighted (**p* < 0.05).

Variable	Population (n = 40)	Expandable titanium cages (n = 20)	Autologous graft (n = 20)	Test statistic	<i>p</i> -Value
Age (years)	61.75 ± 10.95	58.5 ± 11.3	65.1 ± 9.8	t = -1.973	0.055
Sex (M:F)	25 vs. 15	2.33:1	1.22:1	-	-
Preoperative mJOA	10.1 ± 3.48	8.95 ± 3.03	11.25 ± 3.5	t = 2.2219	0.0323*
Postoperative mJOA	13.32 ± 3.12	13.75 ± 2.15	12.9 ± 3.78	t = 0.8741	0.3875
ΔmJOA score	3.5 ± 1.95	4.8 ± 1.85	2.2 ± 0.87	t = 5.6876	0.0001*
Blood loss (mL)	446.25 ± 257.0	520 ± 263.78	372.5 ± 227.75	t = 1.8928	0.0660
Surgical time (min)	252.3 ± 70.17	246.15 ± 33.34	258.45 ± 92.32	t = 0.5785	0.5604
Complications (n)	6	2	4	OR = 0.4444	0.3841
Hospital stay (days)	14.1 ± 14.64	13.8 ± 17.5	14.35 ± 11.27	t = 0.9066	0.1182
Levels treated	1.97 ± 0.8	2.2 ± 0.9	1.75 ± 0.62	t = 1.8414	0.0734
Etiology					
Degenerative	30 (75%)	13 (65%)	17 (85%)	OR = 3.05	0.153
Traumatic	7 (17.5%)	6 (30%)	1 (5%)	OR = 8.14	0.064
Infectious	1 (2.5%)	0	1 (5%)	OR = 3.15	0.489
Other	2 (5%)	1 (5%, Klippel-Feil syndrome)	1 (5%, previous surgery) ^a	OR = 3.15	1.00

mJOA, modified Japanese Orthopaedic Association score; ΔmJOA score, postoperative – preoperative score; OR, odds ratio. Values are expressed as mean ± standard deviation unless otherwise noted.

^a Failed previous anterior cervical discectomy and fusion.

* Statistically significant.

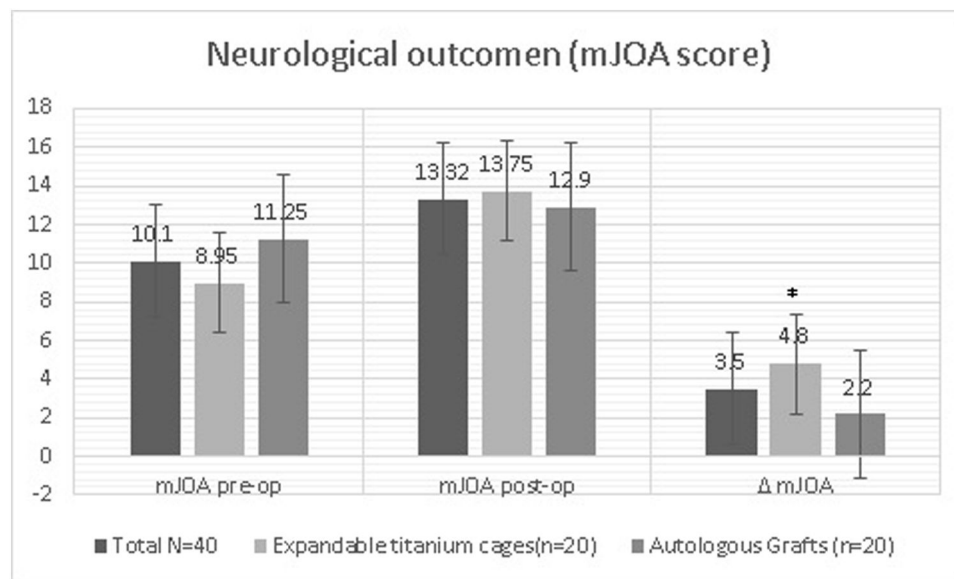


Fig. 3. Neurological outcomes pre- and postoperatively. Bar chart comparing preoperative and postoperative modified Japanese Orthopaedic Association (mJOA) scores in both groups. The expandable titanium cages group showed a significantly greater improvement, despite lower baseline scores.

Postoperative complications occurred in two patients in the ADD plus™/Te-Corp® group and in four patients in the autologous graft group. The odds ratio for complications was 0.4444 (*p* = 0.3841), suggesting no statistically significant difference between groups.

Levels treated

Patients in the expandable titanium cages group had a higher number of vertebral levels treated (2.2 ± 0.9 vs. 1.75 ± 0.62), although this was not statistically significant (*p* = 0.0734).

Discussion

This study provides a comparative evaluation of expandable titanium cages (ADD plus™/Te-Corp™) versus autologous grafts (fibula or iliac crest) in anterior spinal reconstruction.

The use of expandable titanium cages in cervical corpectomy is well-supported in the literature due to their advantages over autogenous bone grafts, such as eliminating donor site morbidity, providing immediate structural support, and facilitating precise height restoration and maintenance of sagittal alignment.

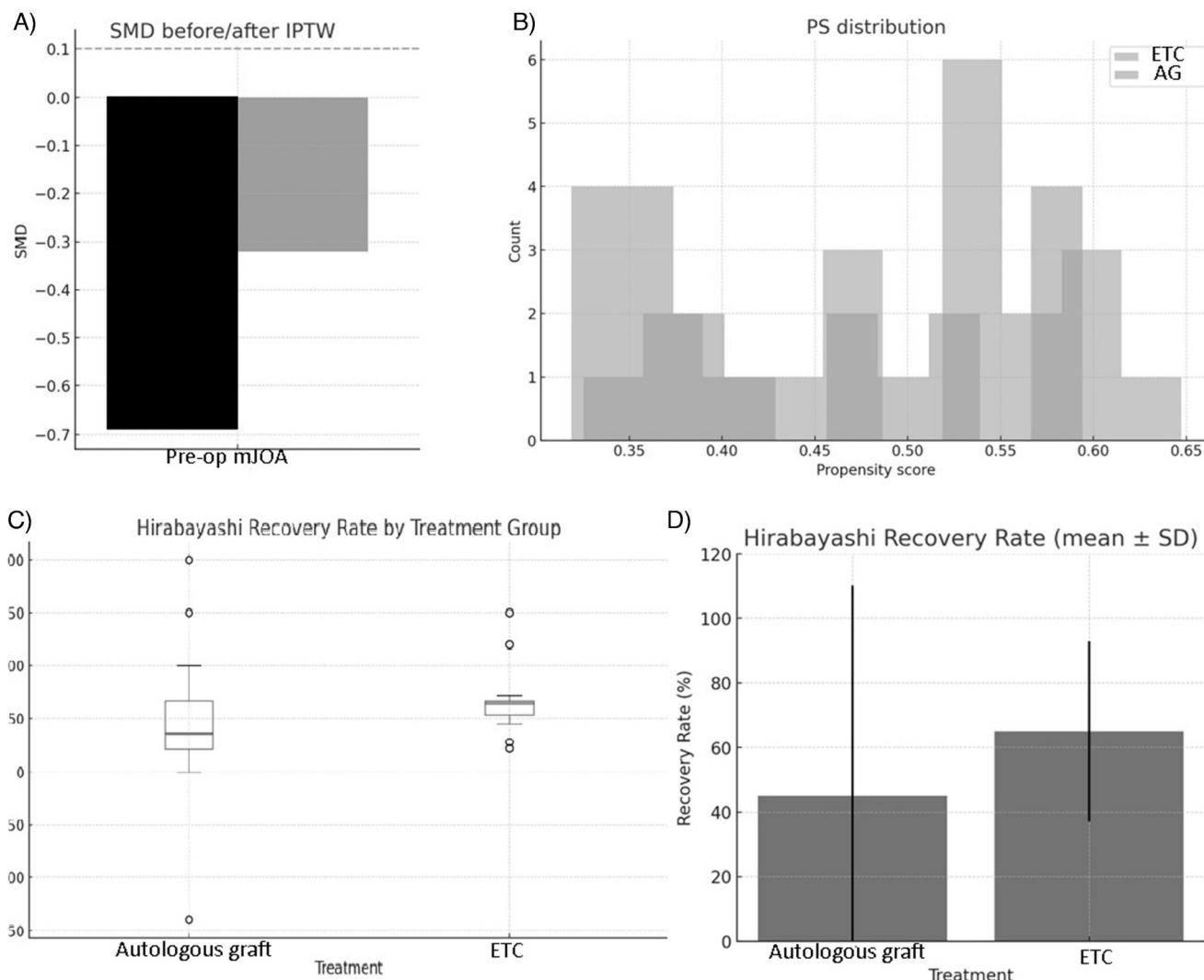


Fig. 4. (A) Standardized mean difference (SMD) before and after applying inverse probability of treatment weighting (IPTW). The SMD measures the balance of patient characteristics between the two treatment groups. An SMD value less than 0.1, indicated by the dashed line, suggests good balance. The black bars show the unweighted data, which had a significant imbalance in the baseline mJOA pre score. The light gray bars show the IPTW-weighted data, which are much closer to zero, indicating that the groups are now more balanced. (B) This histogram displays the distribution of propensity scores (PS) for the two treatment groups: expandable titanium cages (ETC) and autologous graft (AG). The graphs' purpose is to check for adequate overlap between the two distributions, which is a key assumption for IPTW analysis. The graph shows sufficient overlap between the two groups. (C) The boxplot shows the distribution of Hirabayashi recovery rates. ETC demonstrate higher and more consistent recovery rates compared with autologous grafts. (D) Bar chart of mean Hirabayashi recovery rate with standard deviations. ETC group shows higher mean recovery (65.0%) compared to autologous graft (45.1%).

Studies by Zaïri et al.²⁷ and Awad et al.²⁸ generally affirm the favorable clinical and radiological outcomes associated with expandable cages for cervical spondylotic myelopathy. Prakash et al.,²⁹ focusing on winged expandable titanium cages, also reported considerable clinical improvement, aligning with the overall positive perception of these implants. Despite the relatively small sample size, our findings contribute to the growing body of evidence suggesting that expandable titanium cages are a viable and potentially superior alternative to traditional grafting techniques, particularly in terms of early neurological recovery.

Regarding patient demographics, the mean age of our study population was 61.75 ± 10.95 years (ranging from 28 to 82 years). This age profile is consistent with other studies in the field, such as Das et al.³⁰ (59.5–60.9 years), Pojskic et al.³¹ (61.3 years), and Zaïri et al.²⁷ (60 years), indicating that our cohort represents an older patient population often affected by complex cervical pathologies. However, when compared to other cohorts like Patil et al.³² (45.2 ± 16.6 years), Burkett et al.³³ (48 years), and Prakash et al.²⁹ (39.74 years), the mean age in our study was considerably higher. This difference, potentially ranging

from 13 to 22 years, highlights variations in patient populations across different institutions and regions, which might influence surgical indications, outcomes, and complication profiles. Consistent with the broader literature, there was a generalized male predominance observed in our study population.

However, our findings present a notable point of divergence when compared to some existing literature. Specifically, Patil et al.³² in a retrospective descriptive study comparing expandable cylindrical cages to iliac crest autografts a comparison directly analogous to ours found no significant differences in clinical improvement (including neurological presentation) between the two groups. This stands in direct contrast to our observed statistically significant superior mJOA improvement in the expandable cage group. Possible reasons for this discrepancy could include differences in patient populations, specific expandable cage designs (our study utilized the ADD plus™/Te-Corp™ system), surgical techniques, variations in postoperative rehabilitation protocols, or differences in the assessment methodology of clinical improvement.

Patients treated with ETC implants exhibited significantly greater improvement in mJOA scores at three months postoperatively (Δ mJOA = 4.8) compared to those who underwent reconstruction with autologous bone grafts (Δ mJOA = 2.2; $p = 0.0001$). This superior neurological recovery occurred despite a worse baseline neurological status in the ETC group, suggesting a more effective decompression and stabilization of the spinal cord when using expandable cage systems. These results align with those of Awad et al.,²⁶ who reported an average mJOA increase of 3.3 points and a 97% fusion rate in a review of 143 cases of cervical spondylotic myelopathy treated with expandable cages.

Keshavarzi et al.³⁴ also reported excellent outcomes with expandable cages in thoracolumbar reconstructions performed for neoplastic, infectious, or traumatic etiologies, with no postoperative neurological deterioration and high rates of sagittal balance restoration. While their study focused on a broader anatomical and pathological spectrum, their conclusions support the biomechanical and clinical advantages of expandable cage systems in anterior column reconstruction.

Furthermore, a systematic review and meta-analysis by Das et al.³⁰, which compared expandable and non-expandable cages (rather than autografts), also concluded that there was no significant difference in JOA score improvement between these two types of cages. While this comparison is distinct from ours (cage vs. cage versus cage vs. autograft), it introduces nuance by suggesting that even within the realm of prosthetic implants, a clear superiority in neurological outcome is not universally established across all designs. Our study focusses on the comparison with autografts, where a significant difference was found, highlights the continued relevance of evaluating these older versus newer reconstructive methods. The larger effect size observed in our study (4.8 vs. 2.2 delta mJOA) might reflect a more pronounced benefit in our specific cohort or with the particular implant system used.

Surgical parameters such as operative time and hospital stay did not differ significantly between groups in our study, consistent with prior literature. However, a trend toward greater intraoperative blood loss was observed in the ADD plus™/Te-Corp™ group (520 ± 263.78 mL vs. 372.5 ± 227.75 mL), likely attributable to the higher number of levels treated in this group (2.2 vs. 1.75). Similar findings have been reported by Keshavarzi et al.,³⁴ who noted increased blood loss in multilevel reconstructions but found the overall complication rates to be low and manageable.

Our study also reaffirms that expandable cages facilitate intraoperative adaptability and ease of placement. Unlike mesh cages or structural grafts, which require precise sizing and forceful impaction, expandable devices allow for in situ adjustment to the defect, minimizing the risk of endplate violation or over distraction a concern echoed in the literature by Awad et al.²⁸ and other biomechanical studies. Moreover, the broad surface contact of the expandable cage enhances endplate load distribution, potentially improving fusion conditions despite a smaller central graft cavity.

With respect to complications, no statistically significant differences were observed between groups. The ETC group had a slightly lower complication rate (2 vs. 4 patients), although the difference was not statistically significant. This aligns with prior data showing complication rates below 10% for expandable cages used in cervical and thoracolumbar regions. Importantly, none of our patients experienced cage migration, neurological deterioration, or need for reoperation within the follow-up period.

It is noteworthy that the preoperative mJOA scores were significantly different between the groups ($p = 0.0323$), with the autologous graft group having a higher mean mJOA score (indicative of better baseline neurological function). Despite this, the expandable cage group demonstrated a more substantial change in mJOA, further emphasizing its efficacy in promoting neurological recovery, even from a potentially more severe baseline, or demonstrating its ability to achieve greater functional gains. Furthermore, a trend towards older age was observed in the autologous graft group, although this difference did not reach statistical significance ($p = 0.055$).

Besides, the Hirabayashi recovery rate,^{24,25} a standardized metric derived from the Japanese Orthopedic Association (JOA) score,²² is an essential tool for objectively evaluating postoperative neurological improvement in patients with myelopathy. In our pilot study, although the use of expandable titanium cages showed a superior recovery rate (65.0%) compared to autologous bone grafts (45.1%), our findings suggest that the degree of neurological recovery is more strongly influenced by the preoperative severity of the myelopathy than by the specific surgical system used.

This result is consistent with existing literature, which has shown that decompressive interventions, such as laminoplasty and corpectomy, can achieve significant regression of neurological symptoms and, in some cases, complete recovery, as noted by Dmitrievich et al.³⁵

Varying recovery rates have been reported in different studies, highlighting the diversity of outcomes depending on the pathology and technique. For example, Tunturk et al.³⁶ reported a recovery rate of 83.3% after hemilaminectomy for thoracic spinal stenosis, while a study on cervical corpectomy for ossification of the posterior longitudinal ligament (OPLL) recorded a rate of 67.01%. Similarly, Lu et al.³⁷ found no statistical difference in the 58.1% recovery rate in patients over 70 years old compared to a younger control group. Additionally, Du et al.³⁸ concluded that both anterior cervical discectomy and fusion (ACDF) and anterior cervical corpectomy and fusion (ACCF) can result in satisfactory neurological outcomes with no significant difference in the Hirabayashi recovery rate between the two techniques.

The results of our study, although preliminary, reinforce the idea that effective neural decompression is the primary factor in neurological improvement, rather than the choice of reconstruction technique. The consistency with the literature suggests that both expandable titanium cages and autologous grafts are viable options and that the baseline severity of the myelopathy is a key predictor of recovery potential.

These findings support the use of artificial implants as a viable alternative to autologous grafts, especially in patients with multiple-level pathology or when donor site morbidity is a concern.

Strengths and limitations

Strengths of this study include its direct head-to-head comparison between autologous grafts and a modern expandable cage system, standardized inclusion criteria, and the use of validated outcome measures (mJOA). Additionally, all procedures were performed at a single institution by experienced spine surgeons, minimizing variability in surgical technique. The detailed statistical analysis, including correlation assessments and subgroup comparisons, allowed for a nuanced understanding of how surgical factors such as operative time, blood loss, and level of intervention relate to neurological improvement. This adds granularity to the evaluation of clinical outcomes beyond simple pre- and postoperative comparisons.

This study has some limitations inherent to its retrospective, observational, and comparative design. Being a single-center study, the generalizability of our findings may be limited. The relatively small sample size ($n = 40$, 20 patients per group) and the minimum follow-up period of three months restrict the ability to draw definitive long-term conclusions about stability, fusion rates, and the incidence of late complications such as adjacent segment disease or hardware failure. While our analysis suggests trends such as a moderate correlation between operative time and mJOA improvement, these findings should be interpreted cautiously due to the limited statistical power.

The main limitation of our study is the relatively short follow-up period. As a referral hospital, we face the challenge that patients do not have continuous monthly appointments at our center. Instead, we typically schedule follow-ups at 3, 6, and 12 months, with the primary long-term follow-up being carried out at their local, second-level health-care unit. This approach is dictated by the logistics of a high-volume referral center and the need for patients to receive care closer to their homes. While a longer follow-up would provide more definitive data on

fusion rates and late complications, our current data set offers a valuable insight into the short-term neurological outcomes and provides a robust foundation for a larger, multi-center study.

Future research should include larger, prospective, multi-center studies with extended follow-up periods to validate these findings, particularly regarding the potential superiority of expandable cages over autografts in neurological recovery. Direct comparative trials employing standardized outcome measures and assessing specific expandable cage designs will be crucial to clarify existing controversies and provide more robust evidence for clinical decision-making.

Conclusions

The findings of this pilot study suggest that both autologous bone grafts and expandable titanium cages are safe and effective surgical options for spinal decompression and stabilization via corpectomy. A key finding from our analysis, adjusted for baseline differences in mJOA scores, is that we found no statistically significant difference in final neurological outcomes between the two systems.

This result is clinically relevant as it indicates that postoperative neurological recovery is primarily driven by the severity of the patient myelopathy at the time of surgery, rather than by the type of implant material used. The IPTS analysis confirmed this relationship, demonstrating that patients with more advanced myelopathy (lower mJOA scores) have a greater potential for neurological improvement.

While this study is not large enough to establish the superiority of one system over another, it does validate both as viable options in clinical practice.

The results provide crucial preliminary evidence that can guide decision-making, suggesting that the choice between an autologous graft and an expandable cage could be based on other factors, such as cost, implant availability, surgical time (as discussed in the results), or surgeon preference, without compromising the patient's short-term neurological outcome.

Despite the limited follow-up, this study lays the groundwork for future research, underscoring the need for larger, multi-center studies to not only validate these findings but also to examine long-term outcomes, including fusion rates and the incidence of late complications.

CRedit authorship contribution statement

Conceptualization: AMPG, JCLV, UGG. Formal analysis: AMPG, JCLV. Investigation: AMPG, DAVM, JCLV. Methodology: AMPG, JCLV, UGG. Project administration: OMC, AIDT, UGG. Writing – original draft: AMPG, DAVM, JCLV. Writing – review & editing: AMPG, JCLV, UGG.

References

- Louie PK, Nemani VM, Leveque JA. Anterior cervical corpectomy and fusion for degenerative cervical spondylotic myelopathy: case presentation with surgical technique demonstration and review of literature. *Clin Spine Surg.* 2022;35(10):440–446.
- Falavigna A, Piccoli Conzatti L. Minimally invasive approaches for thoracic decompression from discectomy to corpectomy. *J Neurosurg Sci.* 2013;57(3):175–192.
- Hartmann S, Wipplinger C, Tschugg A, et al. Thoracic corpectomy for neoplastic vertebral bodies using a navigated lateral extracavitary approach—a single-center consecutive case series: technique and analysis. *Neurosurg Rev.* 2018;41(2):575–583.
- Trungu S, Ricciardi L, Forcato S, et al. Anterior corpectomy and plating with Carbon-PEEK instrumentation for cervical spinal metastases: clinical and radiological outcomes. *J Clin Med.* 2021;10(24):5910.
- Ozgen S, Naderi S, Ozek MM, Pamir MN. A retrospective review of cervical corpectomy: indications, complications and outcome. *Acta Neurochir (Wien).* 2004;146(10):1099–1105 [discussion 1105].
- Hirai T, Yoshii T, Sakai K, et al. Anterior cervical corpectomy with fusion versus anterior hybrid fusion surgery for patients with severe ossification of the posterior longitudinal ligament involving three or more levels: a retrospective comparative study. *J Clin Med.* 2021;10(22):5315.
- Schulz C, Mauer UM, Mathieu R. Implantatassoziierte Komplikationen sowie klinischer und radiologischer Verlauf nach anteriorer zervikaler Korpektomie und Cage-Fusion – retrospektiver Vergleich von PEEK-gegen Titan-Cages [Clinical and radiological results after anterior cervical corpectomy with cage fusion – a retrospec-

- tive comparison of PEEK vs. titanium cages]. *Z Orthop Unfall.* 2017;155(2):201–208 [in German].
- Tome-Bermejo F, Álvarez-Galovich L, Piñera-Parrilla ÁR, et al. Anterior 1-2 level cervical corpectomy and fusion for degenerative cervical disease: a retrospective study with lordotic porous tantalum cages. Long-term changes in sagittal alignment and their clinical and radiological implications after cage subsidence. *Int J Spine Surg.* 2022;16(2):222–232.
- Han YC, Liu ZQ, Wang SJ, Li LJ, Tan J. Is anterior cervical discectomy and fusion superior to corpectomy and fusion for treatment of multilevel cervical spondylotic myelopathy? A systemic review and meta-analysis. *PLoS One.* 2014;9(1):e87191.
- Wang T, Wang H, Liu S, An H-D, Liu H, Ding W-Y. Anterior cervical discectomy and fusion versus anterior cervical corpectomy and fusion in multilevel cervical spondylotic myelopathy. *Medicine (Baltimore).* 2016;95:e5437.
- Yee TJ, Swong K, Park P. Complications of anterior cervical spine surgery: a systematic review of the literature. *J Spine Surg.* 2020;6(1):302–322.
- Yeh MY, Huang WC, Kuo CH, Chang PY, Cheng H. Disappearance of anterior cervical corpectomy cage. *Cureus.* 2019;11(1), e3985.
- Boakye M, Patil CG, Ho C, Lad SP. Cervical corpectomy: complications and outcomes. *Neurosurgery.* 2008;63(4 (suppl 2)):295–301 [discussion 301–2].
- Monk SH, O'Brien M, Perle S, et al. Ten-year experience of skip anterior cervical corpectomy and fusion. *Int J Spine Surg.* 2023;17(2):258–264.
- Uribe JS, Sangala JR, Duckworth EA, Vale FL. Comparison between anterior cervical discectomy fusion and cervical corpectomy fusion using titanium cages for reconstruction: analysis of outcome and long-term follow-up. *Eur Spine J.* 2009;18(5):654–662.
- Tatter C, Persson O, Burström G, Edström E, Elmi-Terander A. Anterior cervical corpectomy and fusion for degenerative and traumatic spine disorders, single-center experience of a case series of 119 patients. *Oper Neurosurg (Hagerstown).* 2020;20(1):8–17.
- Singh V, Kern K. Vertebral body replacement devices. In: Wang MY, ed. *Instrumentation for minimally invasive spine surgery.* New York: Thieme; 2021:173–182, <http://dx.doi.org/10.1055/b-0041-179981>.
- Meena A, Choudhary L, Karan R. A systematic review of the use of expandable cages in the cervical spine. *Int J Pharm Clin Res.* 2023;15(7):1442–1447.
- Tohamy MH, Osterhoff G, Abdelgawaad AS, Ezzati A, Heyde CE. Anterior cervical corpectomy and fusion with stand-alone cages in patients with multilevel degenerative cervical spine disease is safe. *BMC Musculoskelet Disord.* 2022;23(1):20.
- Schulz C, Mauer UM, Mathieu R. Implantatassoziierte Komplikationen sowie klinischer und radiologischer Verlauf nach anteriorer zervikaler Korpektomie und Cage-Fusion – retrospektiver Vergleich von PEEK-gegen Titan-Cages [Clinical and radiological results after anterior cervical corpectomy with cage fusion – a retrospective comparison of PEEK vs. titanium cages]. *Z Orthop Unfall.* 2017;155(2):201–208 [in German].
- Hoffman H, Goulart CR, Galgano MA. Utilizing vertebral body autograft for anterior cervical corpectomy/fusion. *Surg Neurol Int.* 2020;11:24.
- Benzel EC, Lancon J, Kesterson L, Hadden T. Cervical laminectomy and dentate ligament section for cervical spondylotic myelopathy. *J Spinal Disord.* 1991;4:286–295.
- STROBE. *Strengthening the reporting of observational studies in epidemiology.* STROBE; 2025. Available from: <https://www.strobe-statement.org> [Last visit: 31 March 2025].
- Hirabayashi K, Satomi K. Operative procedure and results of expansive open-door laminoplasty. *Spine.* 1988;13:870–876.
- Hirabayashi K, Watanabe K, Wakano K, Suzuki N, Satomi K, Ishii Y. Expansive open-door laminoplasty for cervical spinal stenotic myelopathy. *Spine.* 1983;8:693–699.
- Son DK, Son DW, Song GS, Lee SW. Effectiveness of the laminoplasty in the elderly patients with cervical spondylotic myelopathy. *Korean J Spine.* 2014;11(2):39–44, <http://dx.doi.org/10.14245/kjs.2014.11.2.39>.
- Zairi F, Aboukais R, Thines L, Allaoui M, Assaker R. Relevance of expandable titanium cage for the treatment of cervical spondylotic myelopathy. *Eur Spine J.* 2012;21:1545–1550, <http://dx.doi.org/10.1007/s00586-012-2380-2>.
- Awad AJ, Stidd DA, Alkhalili K, Eli IM, Baaj AA. Vertebral body reconstruction using expandable titanium cages after anterior decompression for cervical spondylotic myelopathy: a review. *Cureus.* 2013;5(5):e165, <http://dx.doi.org/10.7759/cureus.165>.
- Prakash A, Bharti R, Chauhan G, Dutta G, Sahay CB. Outcome associated with use of winged expandable titanium cage following cervical corpectomy: an institutional experience. *Egypt J Neurosurg.* 2024;39:20, <http://dx.doi.org/10.1186/s41984-024-00288-3>.
- Das AK, Purohit DK, Gupta A, Kataria R. Comparison of radiological and clinical outcomes between expandable and non-expandable cages following cervical corpectomy: a systematic review and meta-analysis. *Asian Spine J.* 2023;17(3):567–581, <http://dx.doi.org/10.31616/asp-2022.0179>.
- Pojiskic M, Saß B, Nimsky C, Carl B. Application of an expandable cage for reconstruction of the cervical spine in a consecutive series of eighty-six patients. *Medicina.* 2020;56:642, <http://dx.doi.org/10.3390/medicina56120642>.
- Patil SG, Balasubramaniam S, Pramod G. Analysis of outcome in cases of cervical corpectomy with fusion by autograft and expandable corpectomy cage. *Int J Dent Med Sci Res.* 2021;3(6):578–586.
- Burkett CJ, Baaj AA, Dakwar E, Uribe JS. Use of titanium expandable vertebral cages in cervical corpectomy. *J Clin Neurosci.* 2012;19:402–405.
- Keshavarzi S, Newman CB, Ciacci JD, Aryan HE. Expandable titanium cages for thoracolumbar vertebral body replacement: initial clinical experience and review of the literature. *Am J Orthop (Belle Mead NJ).* 2011;40(3):E35–E39 [PMID: 21720606].
- Dmitrievich DM, Olegovich AS, Vazgenovich PD, et al. Laminoplasty and corpectomy in the treatment of cervical spondylotic myelopathy. *Coluna/Columna.* 2018;17(3):174–179.

36. Tümtürk A, Meral M, Kucuk A, Ulutabanca H, Koç RK. Hemilaminectomy and bilateral decompression for thoracic spinal stenosis. *Turkish Neurosurg.* 2020;30(6):842–846.
37. Lu J, Wu X, Li Y, Kong X. Surgical results of anterior corpectomy in the aged patients with cervical myelopathy. *Eur Spine J.* 2008;17(1):129–135.
38. Du W, Wang HX, Lv J, et al. Cervical alignment and clinical outcome of anterior cervical discectomy and fusion vs. anterior cervical corpectomy and fusion in local kyphotic cervical spondylotic myelopathy. *Heliyon.* 2023;9(8):e19106.