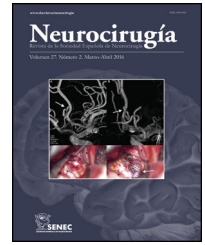




NEUROCIRUGÍA

www.elsevier.es/neurocirugia


Clinical Research

Comparison of clinical efficacy of MMA embolization combined with subdural perforation drainage and subdural perforation drainage in the treatment of CSDH



Wen Cheng*, Quanlong Yang, Xiaodong Yuan, Jiangbin Wu

Neurosurgery, Affiliated Hospital and Clinical Medical College of Chengdu University, No. 82, North Section 2, Second Ring Road, Jinniu District, Chengdu, Sichuan, China

ARTICLE INFO

Article history:

Received 30 May 2024

Accepted 17 October 2024

Keywords:

Chronic subdural hematoma

Middle meningeal artery embolization

Subdural drilling and drainage

Clinical effect

Surgical method

ABSTRACT

Background: Chronic subdural hematoma is a frequent neurosurgical illness, and current treatment options mostly include subdural trepanation and drainage alone, as well as middle meningeal artery embolization in conjunction with subdural trepanation and drainage. However, there is currently a lack of extensive study and data support for comparing the clinical results of the two surgical treatment techniques.

Objective: The goal of this study is to compare the clinical effects of middle meningeal artery embolization combined with subdural trepanation and drainage versus simple subdural trepanation and drainage in the treatment of chronic subdural hematoma, in order to provide a reliable foundation for clinical selection of appropriate surgical treatment methods.

Methods: This study included 71 patients with chronic subdural hematoma, who were divided into two groups according to the procedure: observation group (n = 25) and control group (n = 46). The control group received only basic subdural drilling and drainage.

Conclusions: This study found that MMA embolization combined with subdural trepanation and drainage provides a greater therapeutic benefit in the treatment of chronic subdural hematoma. The observation group outperformed the control group in terms of postoperative CT results, Barthel index, and clinical effect, as well as operating time. Furthermore, the observation group's complications and recurrence rate were much lower than the control group's.

© 2024 The Authors. Published by Elsevier España, S.L.U. on behalf of Sociedad Española de Neurocirugía. This is an open access article under the CC BY-NC-ND license (<http://creativecommons.org/licenses/by-nc-nd/4.0/>).

DOI of original article: <https://doi.org/10.1016/j.neucir.2024.10.003>.

* Corresponding author.

E-mail address: chengwen2002112@163.com (W. Cheng).

<https://doi.org/10.1016/j.neucir.2024.11.001>

2529-8496/© 2024 The Authors. Published by Elsevier España, S.L.U. on behalf of Sociedad Española de Neurocirugía. This is an open access article under the CC BY-NC-ND license (<http://creativecommons.org/licenses/by-nc-nd/4.0/>).

Comparación de la eficacia clínica de la embolización de la arteria media meningeal combinada con drenaje de perforación subdural y drenaje de perforación subdural en el tratamiento del hematoma subdural crónico

R E S U M E N

Palabras clave:

Hematoma subdural crónico
Embolización de la arteria media meningeal
Drenaje por perforación subdural
Efecto clínico
Método quirúrgico

Antecedentes: El hematoma subdural crónico es una enfermedad neuroquirúrgica frecuente. Las opciones de tratamiento actuales incluyen principalmente el drenaje de perforación subdural solo, así como la embolización de la arteria media meningeal combinada con el drenaje de perforación subdural. Sin embargo, actualmente hay una falta de estudio exhaustivo y apoyo de datos para comparar los resultados clínicos de las dos técnicas de tratamiento quirúrgico.

Objetivo: Comparar los efectos clínicos de la embolización de la arteria media meningeal combinada con el drenaje de perforación subdural frente al drenaje de perforación subdural solo en el tratamiento del hematoma subdural crónico. Proporcione una base confiable para la selección clínica de métodos de tratamiento quirúrgico adecuados.

Métodos: Este estudio incluyó 71 pacientes con hematoma subdural crónico. Los sujetos de investigación fueron divididos en dos grupos según los métodos quirúrgicos: grupo de observación (n = 25) y grupo de control (n = 46). El grupo de control solo recibió drenaje de perforación subdural.

Conclusiones: Este estudio encontró que la embolización de la arteria media meningeal combinada con el drenaje de perforación subdural ofrece un mayor beneficio terapéutico en el tratamiento del hematoma subdural crónico. El grupo de observación superó al grupo de control en cuanto a los resultados de la TC postoperatoria, el índice de Barthel y el efecto clínico, así como el tiempo de operación. Además, las complicaciones y la tasa de recurrencia del grupo de observación fueron mucho más bajas que las del grupo de control.

© 2024 The Authors. Publicado por Elsevier España, S.L.U. en nombre de Sociedad Española de Neurocirugía. Este es un artículo Open Access bajo la licencia CC BY-NC-ND (<http://creativecommons.org/licenses/by-nc-nd/4.0/>).

Introduction

Chronic subdural hematoma (CSDH) therapy approaches have been consistently explored and improved in recent years. The combination of Middle meningeal artery embolization (MMA) and subdural trepanation and drainage is a new therapy approach. It has received a lot of attention in clinical practice when compared to the traditional basic subdural trepanation and drainage.^{1–3} Chronic subdural hematoma is a common neurosurgical emergency defined by the progressive development of chronic subdural hematoma after head trauma.^{4,5} Patients frequently experience headaches, nausea, vomiting, and other symptoms, which can progress to neurological dysfunction in severe cases. Early detection and prompt treatment of chronic subdural hematomas are critical for patient rehabilitation.^{6,7} Simple subdural trepanation and drainage^{8,9} can reduce intracranial pressure and relieve symptoms by drilling on the head and draining the hematoma are the most common traditional therapeutic approaches. However, this approach has numerous drawbacks, including significant surgical stress and a high risk of bleeding.^{10,11} Middle meningeal artery embolization (MMA) combined with subdural trepanation and drainage as a new treatment method,^{12,13} the embolic material is inserted into the arterial vessel through interventional means to block the blood supply, reducing the risk of bleeding. The hematoma can be cleared more efficiently when paired with subdural drilling and drainage. A meta-analysis of

the literature revealed that MMA embolization has a lower rate of postoperative recurrence compared to subdural perforation drainage, with no difference in postoperative complication rates.¹⁴ However, rigorous study on the therapeutic benefit of **MMA Embolization combined with subdural perforation drainage** in the treatment of chronic subdural hematoma is still lacking. As a result, the goal of this study is to compare and contrast the therapeutic effects of middle meningeal artery embolization (MMA) combined with subdural trepanation and drainage and simple subdural trepanation and drainage in order to provide a more scientific and accurate treatment plan for clinical practice. We anticipate that the growth of this study will result in a more thorough understanding of the treatment of chronic subdural hematoma, a reference for clinicians when selecting treatment approaches, and a better contribution to patient rehabilitation.

Materials and methods

General information

This was a single-center retrospective continuous clinical cohort research. The research subjects were 71 patients with chronic subdural hematoma diagnosed and treated at Chengdu University's Affiliated Hospital from January 2022 to October 2023. The patients were separated into two groups based on the differences in treatment modalities. The con-

trol group (n=25) had trepanation and drainage along with middle dural artery embolization. All patients who took part in this study did so willingly and gave informed permission. Our hospital's Medical Ethics Committee approved this investigation. We confirmed that all methods have been performed in accordance with the Declaration of Helsinki. Inclusion and exclusion criteria

Inclusion criteria: ① all patients met the diagnostic criteria of chronic subdural hematoma (Chinese Guidelines for craniocerebral trauma Surgery); ② all patients were diagnosed by CT or MRI; ③ no surgical contraindications¹⁵; ④ age > 18 years old; ⑤ unilateral hematoma. Exclusion criteria: ① patients with serious heart, kidney, liver and other important organ diseases; ② coagulopathy; ③ patients with incomplete follow-up data; ④ death occurred.

Research methods

Control group

The operation is performed by subdural perforation drainage. The anesthesia method is local anesthesia; if the patient is unable to cooperate with local anesthesia, intravenous anesthesia or general anesthesia with tracheal intubation is used. The patient was placed in the supine position and the puncture placement point was localised by CT. The middle and posterior 1/3 of the largest level of the haematoma and the scalp were taken as the puncture point. Avoid important blood vessels and functional areas during puncture. A 2–3 cm incision was made at the puncture location, followed by a cut to the skull, the periosteum was peeled off, a drilling device (1–1.5 cm in diameter) was used to drill through the skull, electrocoagulation around the dura mater, and the bleeding was completely stopped. The dura mater was sliced in a cross shape, and a No. 10 silicone tubing was introduced to access the subdural space, resulting in bloody drainage. In the same manner, the drainage tube was rinsed to the temporoparietal and occipital areas. Finally, the surgical incision was sutured layer by layer, and the drainage tube and drainage device were secured. The remaining condition of subdural hematoma was examined by CT scan after the procedure. On the third day following the operation, the drainage tube was withdrawn when there was no bleeding or the hematoma was less than 10 ml. If there is rebleeding or residual hematoma, the indwelling time of the drainage tube can be reduced to less than one week. Changes in vital signs of patients were routinely monitored after operation, and symptomatic treatment such as conventional anti-infection treatment was performed.

Observation group

The patients were supine on the angiography table after local anesthetic (intravenous anesthesia or general anesthesia for tracheal intubation if they were unable to work together). The puncture site was routinely cleaned and towed. Following success, the Seldinger technique was applied, an 8F sheath was placed, and systemic heparin (40 mg bolus injection) was administered. Through a 0.035 in. guide wire +5F 125 cm angiography guide, the guide was superselected to the external carotid artery. By microguide wire, the Marathon and Apollo microcatheters were superselected to the frontal, parietal, and occipital branches of the middle meningeal artery,

respectively. Following microcatheter hand push angiography confirmation, Onyx was progressively injected into the branches in turn for a total of 1.8 ml. After satisfactory angiography and embolization, the puncture point was occluded by vascular occluder to stop bleeding. Continue drilling and drainage as in Section "Control group".

Indicators of observation

Baseline characteristics (age, gender, history of hypertension, diabetes, coronary heart disease, myocardial infarction, cerebral infarction, asthma, cancer, etc.), use of anticoagulant drugs (aspirin, warfarin, etc.), history of head trauma), clinical operation indicators (intraoperative blood loss, operation time, drainage volume, drainage time, length of hospital stay), clinical effect, stroke mRs Score, neurological deficit score (Markwalder). Chronic subdural hematoma progression and recurrence¹⁶ was defined as new high-density hematoma, increased hematoma thickness, and the presentation or exacerbation of clinical symptoms. The hematoma thickness: on CT image, the diameter from the inner plate of skull to the place with the largest hematoma width on the brain surface (unit: mm).

Clinical effect¹⁷

The clinical symptoms and signs of the patients were greatly reduced, and the subdural hematoma almost completely gone. Effective: the patients' clinical symptoms and signs improved, and the subdural hematoma was reduced. Ineffective: none of the following indicators were met, and they even tended to worsen. Total effective rate = (marked effective + effective)/total cases 100%.

The CT was evaluated periodically after operation, and the imaging outcomes at 3 months after operation, Markwalder Score at 1 week after operation and mRs Score at 3 months after operation were recorded

Postoperative CT results: cured, CT examination showed that there was no hematoma. CT examination showed that the clearance rate was more than 90%. CT examination showed that the clearance rate was 75%–90%. Effective, 60%–75%; ineffective, less than 60%.

Barthel index¹⁸: cure, symptoms disappear completely; Obviously improved, symptoms basically disappeared, slight neurological dysfunction; The symptoms were partially improved, and the patient was basically self-care. The symptoms were slightly improved, and the patient could live independently with help. Ineffective, completely unable to take care of themselves.

mRs Score¹⁹: 0: no symptoms; Score 1: symptomatic but without significant neurological impairment, able to perform all daily activities; Score 2: mild disability, unable to complete all pre-illness activities, but able to live independently; Score 3: moderate disability requiring partial assistance but able to walk independently; Score 4: moderate to severe disability, unable to walk independently, requiring partial care for daily life; Score 5: severe disability, bedridden, incontinence, total dependence on others for daily life; Score 6: Death. The mRS Score of 0–2 was defined as good prognosis, and the mRS Score of 3–6 was defined as poor prognosis.

Table 1 – Comparison of general information between the two groups.

Variables	Total (n = 71)	Control group (n = 46)	Observation group (n = 25)	Statistic	P
Age	71.94 ± 14.35	73.07 ± 16.37	69.88 ± 9.57	t = 1.03	0.305
Preoperative hematoma thickness (mm)	19.28 ± 6.29	20.37 ± 6.53	18.27 ± 5.37	t = 2.03	0.076
Midline shift (mm)	5.19 ± 5.06	6.22 ± 4.70	5.32 ± 5.25	t = 2.38	0.350
Gender, n (%)				$\chi^2 = 0.13$	0.722
Male	57 (80.28)	38 (82.61)	19 (76.00)		
Female	14 (19.72)	8 (17.39)	6 (24.00)		
Underlying disease, n (%)				$\chi^2 = 0.35$	0.551
Yes	26 (36.62)	18 (39.13)	8 (32.00)		
No	45 (63.38)	28 (60.87)	17 (68.00)		

Table 2 – Comparison of clinical surgical indexes between the two groups.

Group	Intraoperative blood loss (ml)	Operation time (min)	Volume of drainage (ml)	Drainage time (h)	Length of stay (d)
Control group (n = 46)	32.61 ± 25.88	77.87 ± 31.68	94.59 ± 130.57	58.85 ± 17.90	20.09 ± 11.34
Observation group (n = 25)	48.40 ± 45.06	122.80 ± 56.64	95.92 ± 167.86	53.92 ± 21.25	31.36 ± 36.24
t	–1.88	–3.667	–0.037	1.037	–1.951
P	0.064	<0.001	0.971	0.304	0.055

Statistical methods

The data was analyzed using SPSS25.0 statistical software. Mean standard deviation was used to communicate measurement data, while count (%) was used to convey categorical variables. The median (M), interquartile range (Q), and rank sum test were utilized when the measurement data did not follow the normal distribution. The important indicators of comprehensive collaborative scheduling and quantitative scoring assessment were analyzed using descriptive statistical analysis and one-way analysis of variance. The Chi square test was used to assess the utility of thorough collaborative scheduling and quantitative scoring in increasing operating room efficiency and patient, surgeon, and nurse satisfaction. $P < 0.05$ was regarded as statistically significant.

Results

Comparison of general data between the two groups

There were 38 males and 8 females in the control group. The average age was (73.07 ± 16.37) years (range, 27–96 years). There were 19 males and 6 females in the observation group. The mean age was (69.88 ± 9.57) years (range, 52–95 years). There were no significant differences in age, gender, underlying disease, history of craniocerebral trauma, preoperative hematoma thickness and midline shift between the two groups ($P < 0.05$), which were comparable, the specific results are shown in [Table 1](#).

Comparison of clinical operation indicators between the two groups

The observation group's operation time was longer than the control group's, while the drainage time and hospitalization time were shorter. The intraoperative blood loss and volume of drainage were lower in the observation group than in the control group ($P < 0.05$), and the specific data are provided in [Table 2](#).

Comparison of clinical effects between the two groups

The total effective rate of the observation group was higher than that of the control group, the total effective rate of the observation group was 67.39%, and the total effective rate of the control group was 96.00% ($P < 0.05$). The specific results are shown in [Table 3](#).

Comparison of CT results immediately, 3d, 7d, 30d and 90d after operation between the two groups

By comparing we can find that efficient observation group were higher than the same period in different periods in control group ($P < 0.05$), the observation group 90 days after operation efficiency is as high as 100%. Specific results are shown in [Table 4](#).

Comparison of Barthel index results between the two groups immediately, 3d, 7d, 30d and 90d after operation

Observation group Barthel index in different periods were compared with the control group ($P < 0.05$), the specific results are shown in [Table 5](#).

Incidence of postoperative complications

The incidence of complications in the observation group was lower than that in the control group ($P < 0.05$). The postoperative hematoma thickness, incidence of subdural effusion and mRs Score of the patients were followed up for 3 months after surgery. The incidence of hematoma and subdural effusion and mRs Score in the observation group were lower than those in the control group: the specific results are shown in [Table 6](#).

Comparison of recurrence rates between the two groups

After 6 months of follow-up, the recurrence rate of the observation group was 0 (0/25), which was lower than 39.13% (18/46) of the control group, and the difference was statistically significant ($\chi^2 = 13.105$, $P < 0.001$).

Table 3 – Comparison of clinical therapeutic effects between the two groups.

Group	Remarkable	Effective	Void	Total effective rate
Control group (n = 46)	20 (43.48%)	11 (23.91%)	15 (32.61%)	31 (67.39%)
Observation group (n = 25)	20 (80.00%)	4 (16.00%)	1 (4.00%)	24 (96.00%)
χ^2	–	–	–	7.594
P	–	–	–	0.006

Table 4 – Comparison of CT results between the two groups (%).

Variable		Surgical methods		Effective rate		Statistic	P
		Control group (n = 46)	Observation group (n = 25)	Control group (n = 46)	Observation group (n = 25)		
Immediately after surgery	0	22 (47.83%)	7 (28.00%)	22 (47.83%)	7 (28.00%)	$\chi^2 = 2.635$	0.105
	1	24 (52.17%)	17 (68.00%)	24 (52.17%)	18 (72.00%)		
	2	0 (0)	1 (4.00%)				
3 days after surgery	0	16 (34.78%)	5 (20.00%)	16 (34.78%)	5 (20.00%)	$\chi^2 = 1.699$	0.192
	1	28 (60.87%)	19 (76.00%)	30 (65.22%)	20 (80.00%)		
	2	2 (4.35%)	1 (4.00%)				
7 days after surgery	0	6 (13.04%)	2 (8.00%)	6 (13.04%)	2 (8.00%)	$\chi^2 = 0.412$	0.521
	1	30 (65.22%)	12 (48.00%)	40 (66.67%)	23 (92.00%)		
	2	10 (21.74%)	11 (44.00%)				
30 days after surgery	0	7 (15.22%)	1 (4.00%)	7 (15.22%)	1 (4.00%)	$\chi^2 = 2.038$	0.153
	1	23 (50.00%)	2 (8.00%)	39 (84.78%)	24 (96.00%)		
	2	12 (26.09%)	11 (44.00%)				
	3	4 (8.70%)	11 (44.00%)				
90 days after surgery	0	5 (10.87%)	0 (0)	5 (10.87%)	0 (0.00%)	$\chi^2 = 2.92$	0.087
	1	18 (39.13%)	2 (8.00%)	41 (89.13%)	25 (100.00%)		
	2	7 (15.22%)	4 (16.00%)				
	3	16 (34.78%)	19 (76.00%)				

Table 5 – Comparison of Barthel index results between the two groups.

Variable	Surgical methods		Statistic	P
	Control group (n = 46)	Observation group (n = 25)		
Barthel index score immediately after surgery	66.20 ± 16.81	77.60 ± 13.93	t = -3.059	0.003
Barthel index score at 3 days after operation	71.09 ± 16.63	80.60 ± 12.44	t = -2.502	0.015
Barthel index score at 7 days after operation	75.43 ± 17.35	86.60 ± 14.49	t = -2.739	0.008
Barthel index score at 30 days after operation	80.98 ± 15.83	91.20 ± 13.64	t = -2.723	0.008
Barthel index score at 90 days after operation	87.39 ± 14.09	94.40 ± 11.84	t = -2.112	0.038

Discussion

Chronic subdural hematoma (CSDH) is a frequent neurosurgical illness defined by hematoma accumulation between the dura mater and the pia mater. CSDH is typically caused by head trauma, brain contusion, vascular lesions, or hemorrhagic illness. Treatments for CSDH include middle meningeal artery embolization (MMA) in conjunction with subdural trepanation and drainage, as well as simple subdural trepanation and drainage. These two surgical procedures have distinct advantages and disadvantages, as well as differing short- and long-term clinical outcomes. MMA combined with subdural drilling and drainage is a relatively recent therapy procedure that limits blood supply by embolizing the arteries in the dura mater, limiting the creation of new blood vessels and the rate of hematoma recurrence. Subdural drilling and drainage, on the other hand, can successfully drain the blood and fluid in the hematoma and relieve the symptoms of increased intracranial pressure. In contrast, simple subdural perforation drainage is the traditional treatment. In this method, a drilling

device is used to drill through the skull, the dura is incised with a 'cross' and a 10-gauge silicone hose is placed into the subdural space to drain the haematoma. This approach is straightforward and quick to employ, but because it cannot properly control the creation of new blood vessels, the hematoma recurrence rate is significant, necessitating numerous surgical treatments.

The results of this study showed that during the operation, the operation time of the observation group was significantly longer than that of the control group, which may be due to the increase in the operation time of middle meningeal artery embolization (MMA). However, compared with previous studies,²⁰ we observed no statistically significant differences in drainage time and drainage volume between the observation group and the control group. In addition, the intraoperative blood loss and hospitalization time of the observation group were longer than those of the control group, which was consistent with the results of previous studies,^{21,22} but these differences did not reach statistical significance, and the specific reasons will be analyzed in the

Table 6 – Comparison of postoperative complications between the two groups.

Group	Postoperative hydrocephalus	Postoperative cerebral infarction	Postoperative intracranial infection	New intracerebral hemorrhage after surgery	Intracranial gas or cerebrospinal fluid leakage	Subdural effusion	Blind	Puncture site hematoma	Postoperative hypostatic pneumonia	Overall complication rate
Control group (n = 46)	2 (4.35%)	1 (2.17%)	0	8 (17.39%)	28 (60.87%)	33 (71.74%)	0	0	9 (19.57%)	44 (95.65%)
Observation group (n = 25)	0	1 (4.00%)	0	2 (8.00%)	12 (48.00%)	8 (32.00%)	0	0	5 (20.00%)	16 (64.00%)
χ^2	-	-	-	-	-	-	-	-	-	10.095
P	-	-	-	-	-	-	-	-	-	0.001

limitations of the article later. It should be highlighted that, while a longer procedure duration may increase surgical risk and patient discomfort, the differences we found may be related only to the increased MMA operation time and have no effect on the performance of other surgical measures. As a result, in actual clinical practice, an increase in operation duration may not have a substantial impact on patient recovery and prognosis. Overall, while the observation group showed some patterns that differed from the control group in several ways, these changes were not statistically significant. Further research with a larger sample size may be required to corroborate these findings and assess the real influence of surgery scheduling on patient recovery.

This study delves deeper into the clinical effect; the clinical effect of the observation group was clearly superior to that of the control group. Only 67.39% of the 46 patients in the control group received significant therapeutic response, but 96.00% of the 25 patients in the observation group did. The difference is statistically significant when compared to previous research, and our findings confirm the therapeutic effectiveness of middle meningeal artery embolization (MMA) joint draining.²³ Furthermore, The observation group outperformed the control group in terms of CT results at the immediate postoperative period, days 3, 7, 30 and 90, as well as Barthel Index results, and these differences were statistically significant. The improvement of the CT results reflect the effectiveness of the operation, while the Barthel index used to assess the patient's quality of life. The quality of life in the observation group was significantly better than that in the control group at different time points after surgery, which further verified the advantages of middle meningeal artery embolization (MMA) combined with subdural drilling and drainage in improving the quality of life of patients. Finally, the findings of this study revealed that the observation group fared substantially better than the control group in terms of complications and recurrence rates, with statistically significant differences. This suggests that, when compared to pure subdural drilling drainage, middle meningeal artery embolization (MMA) subdural drilling drainage is more effective in minimising complications and recurrence rate. In comparison to the results always,^{21,24,25} our investigation adds to this conclusion. The reason for this analysis is that middle meningeal artery embolisation is a minimally invasive procedure designed to address the main pathological mechanisms involved in the formation and recurrence of chronic subdural haematomas, and can be used as an adjunctive treatment after subdural perforation drainage. Middle meningeal artery embolisation embolises the middle meningeal artery, persistently blocking the local blood supply and minimising blood leakage.

It is important to note that the conclusion of this study is based on the analysis of the existing literature and finishing, although the results have a certain reliability, but there are still some limitations. From the perspective of a retrospective study, firstly, the observation group was not paired with the control group in a 1:1 ratio, which may have led to potential baseline differences between the two groups. For example, the observation group may have had more severe disease or other unpredictable factors that may have had an effect on the treatment effect. Therefore, the results need to be interpreted with

caution. Secondly, the preoperative hematoma thickness and midline deviation of the observation group were larger, which may indicate that the condition of the observation group was relatively more serious. Furthermore, in the selection of the study population, patients with bilateral haematomas, severe cardiac and renal diseases, and coagulation disorders were excluded. This may have introduced bias, resulting in the group of MMA Embolization combined with subdural perforation drainage being more likely to have a favourable outcome. In addition, the recurrence rate of the control group was 39.13% (18/46). However, nearly 40% of recurrences is very high. This may have been influenced by bias, for example, the patients in control group had more severe underlying diseases, which affected the patients' postoperative recovery and led to postoperative recurrence. Meanwhile, our study is single-centered with a relatively small sample size, therefore, there may be biases in the selection of research subjects.

This selective tendency is likely to skew research conclusions, and other possible intervention treatment effect factors on the observation group cannot be ruled out. As a result, when discussing the study's findings, this issue should be considered as it may create variance. Furthermore, this study is divided into fewer groups and is a single-center study, which limits the popularization and trustworthiness of the results. Small sample sizes may result in statistical underestimation, exposing the findings to random error. The single-center study, on the other hand, may have regional and institute-specific constraints. As a result, more large-scale investigations from many centers are required to validate and corroborate the findings of this study. Therefore, more high-quality, large-sample, multi-center prospective studies should be carried out in the future to further verify this finding and provide more reliable clinical guidance.

In conclusion, middle meningeal artery (MMA) embolization combined with subdural perforation drainage demonstrated significant advantages in terms of surgical outcome, improvement in quality of life, and reduction in complications and recurrence rates. These findings will help to guide clinical practice and provide a better therapy alternative for patients. However, bigger sample sizes and longer follow-up investigations are required to demonstrate the stability and longevity of these findings. Furthermore, the treatment for chronic subdural hematoma should be dependent on the patient's individual condition, the severity of the disease, and the doctor's experience. Because each patient's situation is unique, the treatment approach should be tailored to them.

Conclusions

This study demonstrates that middle meningeal artery embolisation (MMA) combined with subdural perforation drainage has better clinical outcomes in the treatment of CSDH. In addition to the lengthier operation time, the observation group outperformed the control group in terms of postoperative CT results, Barthel index, and clinical outcomes. Furthermore, the observation group had much reduced complications and recurrence rates than the control group. As a result, doctors may consider using middle meningeal artery embolization (MMA) in conjunction with subdural trepanation

and drainage in the treatment of chronic subdural hematoma. This study offers a novel concept and point of reference for the treatment of chronic subdural hematoma.

CRedit authorship contribution statement

Wen Cheng participated in case collection; Jiangbin Wu and Quanlong Yang wrote the manuscript and raised idea; Quanlong Yang and Xiaodong Yuan revised the manuscript and raised critical editing. All authors have read and approved the manuscript.

Ethics statement

Written informed consent was obtained from the individual for the publication of any potentially identifiable images or data included in this article. Approval number: PJ2023-058-03.

Data availability statement

The raw data supporting the conclusions of this article will be made available by the authors, without undue reservation. If you need to ask us for the data of this study, please contact Wen Cheng, chengwen2002112@163.com.

Declaration of competing interest

The authors declare that they have no conflicts of interest.

REFERENCES

1. Vazquez S, Zuckerman DA, Gandhi C, Al-Mufti F, Muh C, Santarelli J, et al. Middle meningeal artery embolization in pediatric patients. *Pediatr Neurosurg*. 2024;59:44–53, <http://dx.doi.org/10.1159/000534895>.
2. De Maria L, Chaurasia B, Agosti E, Garg K, Burkhardt JK, Goehre F, et al. Non-surgical management of chronic subdural hematoma: insights and future perspectives from an international survey including neurosurgeons from 90 countries worldwide. *Int J Neurosci*. 2023;1–10, <http://dx.doi.org/10.1080/00207454.2023.2286202>.
3. Akamatsu Y, Kashimura H, Kojima D, Yoshida J, Chika K, Komoribayashi N, et al. Correlation between low-density hematoma at 1-week post-middle meningeal artery embolization and rapid resolution of chronic subdural hematoma. *World Neurosurg*. 2024;181:e1088–92, <http://dx.doi.org/10.1016/j.wneu.2023.11.045>.
4. Poon MTC, Rea C, Kolias AG, Brennan PM, British. Influence of antiplatelet and anticoagulant drug use on outcomes after chronic subdural hematoma drainage. *J Neurotrauma*. 2021;38:1177–84, <http://dx.doi.org/10.1089/neu.2018.6080>.
5. Wang N, Hu J, Oppong-Gyebi A, Zhu X, Li Y, Yang J, et al. Elevated blood urea nitrogen is associated with recurrence of post-operative chronic subdural hematoma. *BMC Neurol*. 2020;20:411, <http://dx.doi.org/10.1186/s12883-020-01985-w>.
6. Lu T, Guan J, An C. Preoperative trepanation and drainage for acute subdural hematoma: two case reports. *Exp Ther Med*. 2015;10:225–30, <http://dx.doi.org/10.3892/etm.2015.2456>.
7. Hacıyakupoğlu E, Yılmaz DM, Kınalı B, Arpacı T, Akbaş T, Hacıyakupoğlu S. Recurrent chronic subdural hematoma:

- report of 13 cases. *Open Med (Wars)*. 2018;13:520–7, <http://dx.doi.org/10.1515/med-2018-0076>.
8. Xue H, Zhang W, Shi L, Zhang Y, Yu B, Yang H. Subdural empyema complicated after trepanation and drainage of chronic subdural hematoma: a case report. *Medicine (Baltimore)*. 2019;98:e18587, <http://dx.doi.org/10.1097/md.00000000000018587>.
 9. Lee HS, Song SW, Chun YI, Choe WJ, Cho J, Moon CT, et al. Complications following burr hole craniostomy and closed-system drainage for subdural lesions. *Korean J Neurotrauma*. 2018;14:68–75, <http://dx.doi.org/10.13004/kjnt.2018.14.2.68>.
 10. Bockeria L, Golukhova E, Dadasheva M, Revishvili A, Levant A, Bazaev V, et al. Advantages and disadvantages of one-stage and two-stage surgery for arrhythmias and Ebstein's anomaly. *Eur J Cardiothorac Surg*. 2005;28:536–40, <http://dx.doi.org/10.1016/j.ejcts.2005.04.047>.
 11. Cox JL. Cardiac surgery for arrhythmias. *Pacing Clin Electrophysiol*. 2004;27:266–82, <http://dx.doi.org/10.1111/j.1540-8159.2004.00426.x>.
 12. Tavakkoli A, Montejo JD, Calnan DR, Ryken TC, Eskey CJ. Intra-operative emergence of occult dural arteriovenous fistula after middle meningeal artery embolization for chronic subdural hematoma: case report and literature review. *Radiol Case Rep*. 2022;17:1470–4, <http://dx.doi.org/10.1016/j.radcr.2021.12.012>.
 13. Ban SP, Hwang G, Byoun HS, Kim T, Lee SU, Bang JS, et al. Middle meningeal artery embolization for chronic subdural hematoma. *Radiology*. 2018;286:992–9, <http://dx.doi.org/10.1148/radiol.2017170053>.
 14. Ironside N, Nguyen C, Do Q, Ugiliweneza B, Chen CJ, Sieg EP, et al. Middle meningeal artery embolization for chronic subdural hematoma: a systematic review and meta-analysis. *J Neurointerv Surg*. 2021;13:951–7, <http://dx.doi.org/10.1136/neurintsurg-2021-017352>.
 15. Abdelfatah MAR. Recurrence rate of chronic subdural hematoma after evacuating it by two large burr holes, irrigation, and subgaleal low-pressure suction drainage. *Asian J Neurosurg*. 2019;14:725–9, <http://dx.doi.org/10.4103/ajns.AJNS.321.17>.
 16. Abouzari M, Rashidi A, Rezaei J, Esfandiari K, Asadollahi M, Aleali H, et al. The role of postoperative patient posture in the recurrence of traumatic chronic subdural hematoma after burr-hole surgery. *Neurosurgery*. 2007;61:794–7, <http://dx.doi.org/10.1227/01.Neu.0000298908.94129.67>, discussion 7.
 17. Khan HU, Atif K, Boghsani GT. Single versus double burr-hole drainage for chronic subdural hematoma: a study of relevant prognostic factors conducted in Pakistan. *Pak J Med Sci*. 2019;35:963–8, <http://dx.doi.org/10.12669/pjms.35.4.543>.
 18. Balci BP. Spasticity measurement. *Noro Psikiyatrs Ars*. 2018;55:S49–s53, <http://dx.doi.org/10.29399/npa.23339>.
 19. Hua J, Lu J, Tang X, Fang Q. Association between geriatric nutritional risk index and depression after ischemic stroke. *Nutrients*. 2022;14, <http://dx.doi.org/10.3390/nu14132698>.
 20. Kitakaze M, Miyoshi N, Fujino S, Ogino T, Takahashi H, Uemura M, et al. Surgical resection for pelvic retroperitoneal Castleman's disease: a case report and review literature. *Biomed Rep*. 2021;14:29, <http://dx.doi.org/10.3892/br.2021.1405>.
 21. Sato M, Mochizuki Y, Fukuchi M, Fujii K. Middle meningeal artery embolization before craniotomy for infected organizing chronic subdural hematoma: a case report and review of the literature. *Surg Neurol Int*. 2022;13:186, <http://dx.doi.org/10.25259/sni.73.2022>.
 22. Ng S, Derraz I, Boetto J, Dargazanli C, Poulen G, Gascou G, et al. Middle meningeal artery embolization as an adjuvant treatment to surgery for symptomatic chronic subdural hematoma: a pilot study assessing hematoma volume resorption. *J Neurointerv Surg*. 2020;12:695–9, <http://dx.doi.org/10.1136/neurintsurg-2019-015421>.
 23. Di Cristofori A, Remida P, Patassini M, Piergallini L, Buonanno R, Bruno R, et al. Middle meningeal artery embolization for chronic subdural hematomas. A systematic review of the literature focused on indications, technical aspects, and future possible perspectives. *Surg Neurol Int*. 2022;13:94, <http://dx.doi.org/10.25259/sni.911.2021>.
 24. Zong H, Lou Z. Comparison of conventional and extended middle meatal antrostomy for the treatment of antrochoanal polyps. *BMC Surg*. 2023;23:16, <http://dx.doi.org/10.1186/s12893-023-01918-7>.
 25. Park H, Park HJ, Kang HS, Lee EJ. Middle meningeal artery embolization for postoperative supratentorial chronic subdural hematoma occurring after posterior fossa neurosurgery. *J Cerebrovasc Endovasc Neurosurg*. 2021;23:152–8, <http://dx.doi.org/10.7461/jcen.2021.E2020.12.002>.